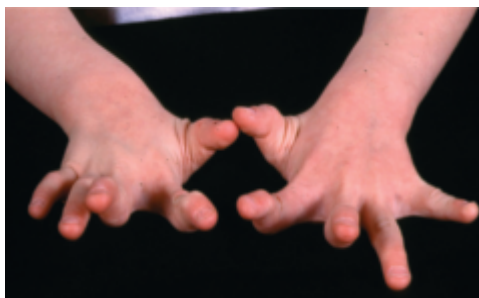

## Joint Hypermobility: Normal Variation or Cause for Concern?

By Deborah Quanbeck, M.D., Kristine Greer, D.P.T., and Katie Wilkins, D.P.T.

Joint hypermobility is a condition in which a person's joints can be flexed beyond the normal range of motion. It affects approximately 10 to 15 percent of children.<sup>1</sup> The diagnosis often appears straightforward—excessive laxity in finger (Fig. 1), elbow, hip and knee joints—and often it is that simple. If there are no other associated symptoms, joint hypermobility is usually considered benign.



**Fig. 1** - A classic example of finger joint hypermobility

Although joint hypermobility alone may not be cause for concern, the condition can be accompanied by joint pain and more frequent injuries (e.g., dislocations, sprains). It also can contribute to arthritis. In some cases, the symptoms signal a more serious condition, such as Ehlers-Danlos syndrome.

When examining a child or adolescent who is unusually flexible or more inclined to have sprains than most children, joint hypermobility may be the cause, and further evaluation is recommended.

### About Joint Hypermobility

Joint hypermobility varies with age, gender (it is more common in females than males) and race. Often, it is familial. The condition is much more common in infants and young children than in adults (people tend to become less flexible as they grow older), and it occurs in a high percentage of Asian children. Randomly ascertained data on school-age children found that 50 percent of Chinese-Asian subjects had joint hypermobility<sup>2</sup> as opposed to 7 percent of English-Caucasians<sup>3</sup>. The average age of onset of symptoms is 6.2 years, but the average age at diagnosis is 9.0 years, indicating a two to three year delay in diagnosis.<sup>4</sup>

### KEY INSIGHTS

- Typically, clinicians discover joint hypermobility when a child is being evaluated for something else, such as joint pain or fatigue, flat feet or bunions, and hip dislocations or subluxations.
- The Beighton scale for assessing joint hypermobility is considered the gold standard for diagnosis, because it is quick, it is easy to use, and it has high intra-rater reliability.
- Nonmusculoskeletal signs and symptoms, such as skin hyperelasticity, excessive bleeding or bruising, prominent veins, or heart murmurs, may point to more serious conditions such as Ehlers-Danlos syndrome.
- Treatment for joint hypermobility depends on the extent of the condition. Physical therapy may suffice for some patients, while others with more involved conditions should be referred to a pediatric orthopedic surgeon or pediatric rehabilitation specialist.

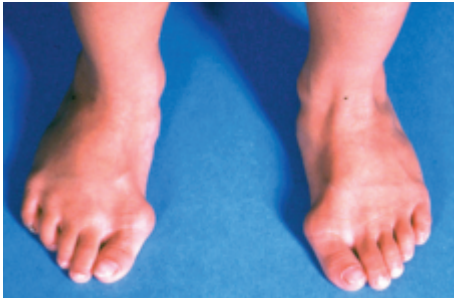### Inside

- Beighton scale for assessing the extent of joint hypermobility, P. 2
- Physical Therapy Can Treat and Prevent Joint Hypermobility Symptoms, P. 3 (inside flap)

## Diagnosing Joint Hypermobility

Typically, clinicians discover joint hypermobility when a child is evaluated for something else, such as:

- Joint pain and/or fatigue
- Deformities such as flat feet, bunions (See Fig. 2.), clubfeet, hip dislocation or subluxation, and developmental dysplasia of the hip (DDH); as many as half of children with DDH have signs of hypermobility
- Joint effusions
- Injuries such as recurrent sprains or dislocations
- Developmental delay
- Clumsiness
- Gait abnormalities



**Fig. 2** - Bunions and flat feet in a nine-year-old boy


At Gillette Children's Specialty Healthcare, we use the Beighton scale to screen for joint hypermobility. The scale assesses only a few joints and is based on four passive maneuvers and one active maneuver. Instead of focusing on the degree of hypermobility at a particular joint, the tool helps clinicians establish how widespread the hypermobility is in that individual. A score of five or more defines generalized joint hypermobility.

Not only is the tool quick and easy to use, but it also provides an objective measure based on a nine-point scale, and it has high intra-rater reliability. As a result, the Beighton scale is considered the gold standard for joint hypermobility assessment.<sup>5</sup>

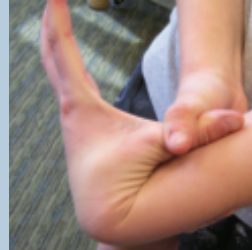
Once the extent of joint hypermobility is established, clinicians should assess nonmusculoskeletal factors, including:

- Skin hyperelasticity, which results from defective collagen molecules in the skin
- Doughy or fragile skin, which tears easily or shows excessive scarring
- Excessive bleeding or bruising
- Physical education difficulties
- Hernias
- Gingival recession
- Prominent veins, hemorrhoids, or early-onset varicose veins
- Blue sclera
- Heart murmurs
- Family history

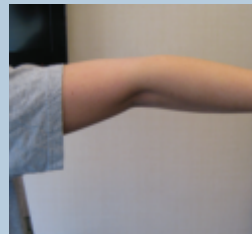## ■ Beighton Scale



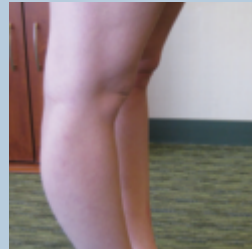Passive dorsiflexion of the metacarpophalangeal joint beyond 90 degrees  
**1 point for each hand**



Passive apposition of the thumb to the flexor aspect of the forearm  
**1 point for each thumb**



Hyperextension of the elbows beyond 10 degrees  
**1 point for each elbow**



Hyperextension of the knees beyond 10 degrees  
**1 point for each knee**



Forward flexion of the trunk with knees fully extended so that the palms of the hands rest flat on the floor  
**1 point**

Evidence of the nonmusculoskeletal signs and symptoms mentioned at left is worrisome, because it points to more serious conditions such as Ehlers-Danlos syndrome, osteogenesis imperfecta, Marfan syndrome and Larsen syndrome.

## About Ehlers-Danlos Syndrome

Joint hypermobility is one of the hallmarks of Ehlers-Danlos syndrome (EDS), an inherited connective tissue disorder. Hyperelastic skin and fragile tissue are also associated with EDS. According to the Villefranche nosology, the syndrome is classified into six main types: classic, hypermobile, vascular, kyphoscoliosis, arthrochalsia and dermatosparaxis.<sup>6</sup>

Kyphoscoliosis, arthrochalsia and dermatosparaxis are rare types of EDS; classic, hypermobile and vascular EDS are considered to be the major types. While classic and hypermobile EDS primarily affect the skin and musculoskeletal system, vascular EDS is of particular concern because of the potential for arterial, bowel or uterine rupture. Consequently, any patient who has joint hypermobility requires a more thorough assessment to establish or rule out EDS.

## Managing Joint Hypermobility

When a serious underlying genetic diagnosis such as Ehlers-Danlos syndrome is suspected, refer the patient for genetic testing, and potentially for assessment of bleeding disorders, mitral valve prolapse or aortic dilation. For concerns about rheumatic conditions, refer the patient to a pediatric rheumatologist.

For less involved cases, in which symptoms are primarily musculoskeletal, refer the patient to a pediatric orthopedic surgeon, a pediatric rehabilitation medicine specialist or a physical therapist—depending on the extent of impairment.

At Gillette, we take an interdisciplinary approach to care and draw on the appropriate specialists to address each patient's chief complaints. For example, a patient who has hip dysplasia will be assessed and may require orthopedic surgery. However, another less involved patient may be referred for physical therapy to address pain, strengthening, proprioception, balance and delays in gross motor skills.

## Conclusion

Patients who present with symptoms of joint hypermobility should have a thorough assessment to determine the extent of the condition and establish whether joint hypermobility is benign or symptomatic of a serious disorder such as EDS.

<sup>1</sup> [http://www.medicinenet.com/hypermobility\\_syndrome/article.htm](http://www.medicinenet.com/hypermobility_syndrome/article.htm)

<sup>2</sup> Cheng J and Chan P. Joint laxity in children. *J Pediatr Orthop.* 1991, 11:752-756.

<sup>3</sup> Carter C and Wilkinson J. Persistent joint laxity and congenital dislocation of the hip. *J Bone Joint Surg Br.* 1964, 40:40-45.

<sup>4</sup> Adib, N., K. Davies, R. Grahame, and KJ Woo. "Joint hypermobility syndrome in childhood. A not so benign multisystem disorder." *Rheumatology (Oxford)* 44 (2005): 744-50.

<sup>5</sup> Byers, P. H., M. Duvic, M. Atkinson, M. Robinow, L.T. Smith, S.M. Krane, M.T. Greally, M. Ludman, R. Matalon, S. Pauker, D. Quanbeck, U. Schwarze. "Ehlers-Danlos Syndrome Type VIIA and VIIB Results from Splice-Junction Mutations or Genomic Deletions that Involves Exon 6 in the COL1A1 and COL1A2 Genes of Type 1 Collagen" Abstract. *American Journal of Medicine Genetics* (1997) Oct 3; 72(1):94-105

<sup>6</sup> Beighton, Peter, Anne De Paepe, Beat Steinmann, and Petros Tsipouras. "Ehlers-Danlos syndrome nosology." *Ehlers-Danlos National Foundation.* 30 Jan. 2008 <<http://www.ednf.org/index.>>. Reprinted from the *American Journal of Medical Genetics in the August 1998 issue of Loose Connections.*

## Physical Therapy Can Address Joint Hypermobility Symptoms

Joint hypermobility syndrome may have these clinical implications:

**Pain** – Patients might experience intermittent or activity-related pain, especially among adolescents who are involved in sports and other activities.

### **Increased fatigue**

### **Fibromyalgia and complex regional pain syndrome**

**Balance** – Patients who have excessive joint hypermobility often have difficulty with balance and may have decreased awareness of a joint's position during movement (impaired **proprioception**).

**Abnormal autonomic responses** – Patients might have postural orthostatic tachycardia syndrome, orthostatic hypotension or orthostatic intolerance.

### **Orthopedic concerns and musculoskeletal injuries** –

Patients might experience:

**Feet** – Pes planus

**Ankles** – Ankle sprains

**Knees** – Patellofemoral pain and patellar instability (subluxation/ dislocation)

**Hips** – Possible hip subluxation (rare to have actual hip dislocation); frequent hip subluxations can result in labral tears.

**Shoulders** – Multidirectional shoulder instability, shoulder impingement

**Spine** – Spondylolisthesis, scoliosis, degenerative disc disease, thinning of discs, stenosis and herniated discs

### **Delays in gross motor skills**

Depending on a patient's needs, our physical therapists will develop a plan that incorporates the following principles and includes some or all of these treatments.

### **Strengthening Exercises**

Patients who have joint hypermobility inherently have low muscular stiffness and joint instability. Gillette's physical therapists focus on strengthening proximal muscle groups (scapular stabilizers and trunk/core muscles) to help improve joint stability. Trunk and core stabilization exercises also help children learn to keep their joints in the neutral and protected range.

### **Proprioception and Balance Training**

Closed chain exercises enhance proprioceptive feedback and assist with control of the joint. Open chain multidirectional exercises may be added in later stages of rehabilitation, if the joints are stable. Static and dynamic balance training helps improve joint stability during functional and recreational activities.

### **Postural Re-education and Joint Protection Principles**

We educate patients about neutral sitting postures, avoiding knee and elbow hyperextension while standing or in quadruped positions, lifting mechanics, and the proper way to carry a backpack.

### **Education on Stretching**

We recommend that patients avoid stretching hypermobile joints to relieve pain. Instead, we focus on strengthening exercises to improve joint stability, which will eventually relieve patients' symptoms.

### **Footwear and Bracing**

Excessive ankle joint laxity and pes planus are more common in patients who have joint hypermobility. We may recommend orthoses, footwear, ankle stabilizing braces and patellar stabilizing braces.

### **Gross Motor Skills**

Children who have joint hypermobility syndrome may have difficulties with coordination or gross motor skills, and physical therapists will evaluate them for delays in gross motor development.

### **Lifelong Physical Activity**

Maintaining an active lifestyle with strengthening exercises can help provide stability to a joint and reduce painful symptoms. Physical therapists can provide instruction on joint protection principles that can help minimize joint overuse during physical activity.



# Author PROFILES



**Deborah Quanbeck, M.D.**

Deborah Quanbeck, M.D., is a board-certified pediatric orthopedic surgeon. She has extensive experience in treating children with acute pediatric orthopedic conditions and a wide variety of musculoskeletal disorders.

She received her medical degree from the University of Minnesota Medical School. Following her orthopedic surgery residency at the University of Minnesota, she completed a fellowship in pediatric orthopedic surgery at Gillette Children's Specialty Healthcare and Shriners Hospitals for Children. She is a member of the Pediatric Orthopaedic Society of North America and the American Academy of Orthopaedic Surgeons. She has published journal articles and made numerous professional presentations.



**Katie Wilkins, D.P.T**

Katie Wilkins earned a doctorate in physical therapy from the University of Minnesota. She gained her first year of experience in sports medicine and orthopedics at the Sports Medicine and Wellness Center in River Falls, Wis. She works at Gillette Children's Specialty Healthcare's Minnetonka Clinic.



**Kristine Greer, D.P.T.**

Kristine Greer earned a doctorate in physical therapy from the University of Minnesota. She began working with adult and pediatric acute care patients at Mercy Hospital in Coon Rapids, Minn. Shortly thereafter, Kristine transitioned into full-time pediatrics at Gillette Children's Specialty Healthcare. She has worked at Gillette's Minnetonka and Maple Grove clinics.



## A Pediatric PERSPECTIVE

*A Pediatric Perspective* focuses on specialized topics in pediatrics, orthopedics, neurology, neurosurgery and rehabilitation medicine.

To subscribe or unsubscribe from *A Pediatric Perspective*, please send an email to [Publications@gillettechildrens.com](mailto:Publications@gillettechildrens.com).

Editor-in-Chief - Steven Koop, M.D.  
Editor - Ellen Shriner  
Designers - Becky Wright, Kim Goodness  
Photographers - Anna Bittner,  
Paul DeMarchi

Copyright 2013. Gillette Children's Specialty Healthcare. All rights reserved.



To make a referral, call 651-325-2200 or 855-325-2200 (toll-free).



### Clinical Education

Visit the Resource Center on our website to find videos and professional presentations. [www.gillettechildrens.org](http://www.gillettechildrens.org)

### Back Issues of *A Pediatric Perspective*

[www.gillettechildrens.org/  
pediatricperspective](http://www.gillettechildrens.org/pediatricperspective)

CHANGE SERVICE  
REQUESTED

## NEWS & NOTES

### *Gillette's Maple Grove Clinic Expands Services*

Our Maple Grove Clinic has expanded our offering of pediatric specialty services. Patients living in the northwestern metropolitan area now have convenient access to these specialists:

**Orthopedics** - Deborah Quanbeck, M.D., Angela Drummond, P.N.P.

**Pediatric rehabilitation medicine** - Supreet Deshpande, M.D., Angela Sinner, D.O.

**Plastic surgery** - Paul Kim, M.D.

**Craniofacial care** - Martha McGrory, P.N.P.

**Neurotrauma care** - Leslie Larson, P.N.P., Amanda Seeley, P.N.P.

**Sleep medicine** - Laurel Wills, M.D.

Additionally, the Maple Grove Clinic provides comprehensive rehabilitation therapies and assistive technology services.