


IN BRIEF:

Topics in Pediatric Orthopedics



Developmental Dysplasia of the Hip (DDH)

By Walter Truong, M.D., pediatric orthopedic surgeon

Overview

DDH is a combination of two pathologies: dysplasia and instability. Dysplasia refers to the shallowness of the acetabulum. Instability refers to the subluxation or dislocation of the femoral head from its appropriate position in the acetabular floor. One in 1,000 children is born with a dislocated hip, and 10 in 1,000 children are born with hip subluxation or dysplasia¹. Risk factors include the 5 Fs: First-born, Feet-first (breech), Female, Flexible (hyperlaxity syndromes), and a positive Family history of DDH.

Signs and Symptoms

Two or more of the risk factors above, or an abnormal exam finding, are indications for further imaging. A systematic exam for DDH includes these steps:

- **Inspect the inguinal and thigh folds**, particularly the posterior folds, looking for any asymmetry. A difference in thigh heights (positive Galeazzi test) and a limitation in abduction may be present. It is important to remember that these side-to-side differences are present in unilateral hip dislocations, but may not identify bilateral hip dislocations.
- **Perform the Barlow maneuver** to test for subluxability of the femoral head. A positive Barlow test has a soft end point as the femoral head slides posterolaterally.
- **Use the Ortolani maneuver** to see if a dislocated hip can be reduced into the acetabulum. A positive Ortolani test feels like a true 'clunk,' as the ball drops back into the cup.

To perform these tests effectively, examine the child on a firm, flat table and stabilize the pelvis during each unilateral exam. Children of walking age may present with a leg length discrepancy or a Trendelenburg gait. The asymmetric thigh folds, positive Galeazzi test and abduction restrictions may all be present at this age. The Barlow and Ortolani maneuvers are very difficult to perform in children older than 6 months of age and thus are less reliable. Treatment and prognosis for older children is quite different than for infants.

Diagnosis

Ultrasound is the test of choice for children who are younger than 6 months of age because it avoids radiation and is effective in visualizing the nonossified femoral head (Figure 1, on back). The femoral head ossification center normally appears when babies are between 4 and 7 months old, but is often delayed in children who have unstable hips. Most providers wait until the baby is at least 6 months old before using X-rays as the test of choice.

Treatment

Children 6 months old or younger are generally placed in a Pavlik harness, which is a dynamic abduction brace. The goal is to keep the hips in a flexed (~90 degrees) and abducted position so the femoral head stays seated in the acetabulum. For located hips, the brace is used for approximately six to 10 weeks; periodically, ultrasounds are used to assess stability and improvement in dysplasia.

For dislocated hips, bracing is attempted for **three to four weeks maximum**. If the hip has not reduced by that time, the brace is abandoned, as prolonged use allows the femoral head to wear away more of the already deficient acetabular rim². If bracing fails, a closed reduction and spica casting under anesthesia is performed with possible arthrogram and possible adductor tenotomy. More severely involved hips with fixed dislocations may require an open reduction with possible pelvic and/or femoral osteotomies. This is more commonly necessary in older children with DDH.

Walter Truong, M.D., is a pediatric orthopedic surgeon who specializes in treating children who have scoliosis, cerebral palsy, various hip pathologies or orthopedic trauma. He participates in research through the University of Minnesota Medical School's Department of Orthopedics and Gillette Children's Specialty Healthcare's James R. Gage Center for Gait and Motion Analysis. He has made a number of professional presentations, and he is a member of the American Academy of Orthopedic Surgeons and the Pediatric Orthopedic Society of North America. He is also a fellow of the Royal College of Surgeons of Canada.

Key Insights

- DDH is a common condition: One in 1,000 children is born with a dislocated hip, and 10 in 1,000 children are born with hip subluxation or dysplasia¹.
- Risk Factors for DDH- Look for the 5 Fs:
 - First born
 - Feet-first (breech)
 - Female
 - Flexible (ligamentous laxity syndrome)
 - Family history of DDH
- Imaging: Request ultrasound for patients < 6 months old. Request X-rays if child is > 6 months old.
- Abduction brace (Pavlik harness) is effective in children < 6 months old.
- Closed reductions, open reductions, and pelvic and femoral osteotomies are other treatments to consider.

¹ Guille JT, Pizzutillo PD, GD MacEwen. Developmental dysplasia of the hip from birth to six months. Journal of the American Academy of Orthopaedic Surgeons. 2000;8(4):232-42.

² Jones GT, Schoenecker PL, Dias LS. Developmental hip dysplasia potentiated by inappropriate use of the Pavlik harness. Journal of Pediatric Orthopedics. 1992 Nov-Dec;12(6):722-6.

INSIDE:

Developmental Dysplasia of the Hip (DDH)

**RETURN SERVICE
REQUESTED**



To make a referral, call
651-325-2200 or
855-325-2200 (toll-free).

200 University Ave. E.
St. Paul, MN 55101
651-325-2200 or 855-325-2200 (toll-free)
www.gillettechildrens.org

Editor - Jason Kelecic
 Writer - Ellen Shriner
 Graphic Designer - Kim Goodness
 Photographers - Anna Bittner,
 Paul DeMarchi



Copyright 2012, Gillette Children's
Specialty Healthcare.

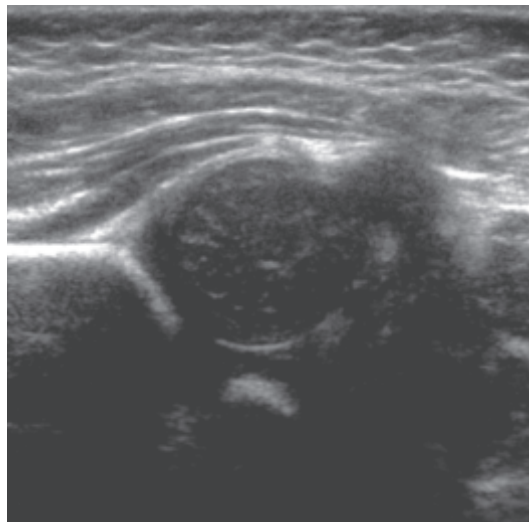


**Gillette Children's Specialty Healthcare is ranked
 12th in the nation for pediatric orthopedics**
 in U.S. News Media Group's 2012-2013 Best Children's Hospitals rankings.

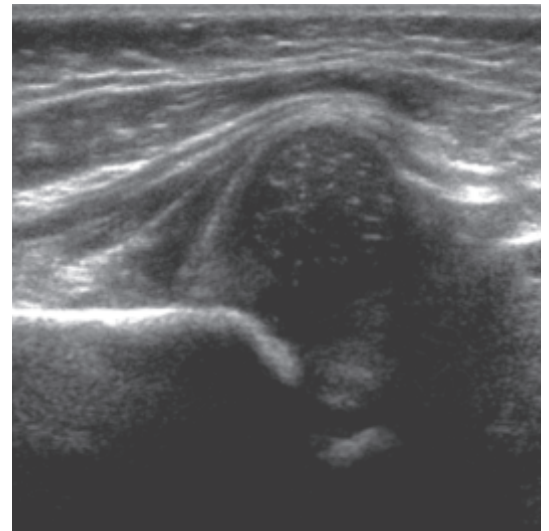
About *InBrief*

InBrief has been developed
 by pediatric orthopedic
 specialists at Gillette
 Children's Specialty
 Healthcare as a resource
 for primary care providers.
 If you have comments or
 questions, please contact
 Jason Kelecic, D.P.T., program
 manager, Center for
 Pediatric Orthopedics, at
jkelecic@gillettechildrens.com.

Developmental Dysplasia of the Hip



A. Right



B. Left

Figure 1: *Ultrasound images of a 1-month-old baby's hips.*
 (A) shows a located right hip and (B) shows a dislocated left hip.